

## **Morton's toe Frequency among the Bulgarian Population and its Association with High Arched Foot**

*Desislava Marinova, Meglena Angelova\*, Veselina Zhekova*

*Department of Anatomy and Cell Biology, Medical University "Prof. Dr. Paraskev Stoyanov",  
Varna, Bulgaria*

\*Corresponding author e-mail: angelovameglena@gmail.com

The human foot must be enough flexible to absorb the ground reaction forces and stiff enough for weightbearing. The medial foot arch has been recognized as a key component in the overall function of the foot. We studied the Morton's toe frequency in Bulgaria among randomly selected men and women aged 18 to 60 years. The foot arch height was investigated. For this purpose we used the common and well established method based on footprints. We combined the measurements of the Clarke angle and the Chippaux-Smirak index to divide the footprints into three groups: normal, high arched and flat foot. Our results show a high prevalence of Morton's toe in the Bulgarian population and a higher frequency of a high arched foot compared to flat one. The statistical data analysis (the  $\chi^2$  test) proved an association between the high arched foot and Morton's toe ( $p \leq 0.05$ ).

*Key words:* foot arch, brachimetatarsia, Morton's toe

### **Introduction**

The human foot plays a key role in supporting the weight of the body, in keeping a stable upright posture and in providing the locomotion. It must be enough flexible to absorb the ground reaction forces and stiff enough for weightbearing. These unique functions of the human foot are defined by its anatomical structure and mainly by its three arches. The medial longitudinal arch is higher than the lateral one and is composed of the calcaneus, the talus, the navicular, the three cuneiforms, and the first, second, and third metatarsals bones. Elasticity is the main characteristic of this arch. The medial arch has an important role in shock absorption and the propulsion during walking and running, so its features have been recognized as a key component in the overall function of the foot during gait [3].

Adequate foot diagnostics requires modern and repeatable technics for assessment of foot construction, based on strictly defined, reliable and repeatable methods of measurement. Morphological examinations use common, simple methods based on

footprint (plantogram) analysis: Arch index, Staheli arch index, Chippaux-Smirak index, Sztriter-Godunow Index, Clarke angle, [7, 9, 12], etc. According to these indices the foot types are classified as normal, high arched foot and flat foot.

The features and shape of the human foot have aroused interest since ancient times. Several types of soles are described according to their shape and toe length. One of the most common is the Greek foot, which can be seen in many statues from ancient Greece: Venus de Milo and also in the Michelangelo's David. This type of foot is characterized with longer second toe compared to the first one. The condition is named Morton's toe after the orthopedic surgeon Dudley J. Morton (1884–1960) in the early 20<sup>th</sup> century [11].

Morton's toe is a congenital condition with brachimetatarsia [8]. In these cases the first metatarsal bone is shorter than the second one. It is usually asymptomatic, but in some occasions the hypermobility or instability of the first metatarsal bone can result in gait changes, in caluses formation and hammertoes [11].

## Materials and Methods

Footprints (plantograms) of randomly selected 102 Bulgarian men and women, without malformations, surgery or traumas of the foot, aged 18 to 60 years were collected after their written consent. The study was approved by the Research Ethics Committee at the Medical University "Prof. Dr. P. Stoyanov" with protocol №140/01.07.2021 and will continue until 600 participants are gathered.

The footprints representing second toe longer with at least 1,5 mm than the first one, were described as Morton's toe positive.

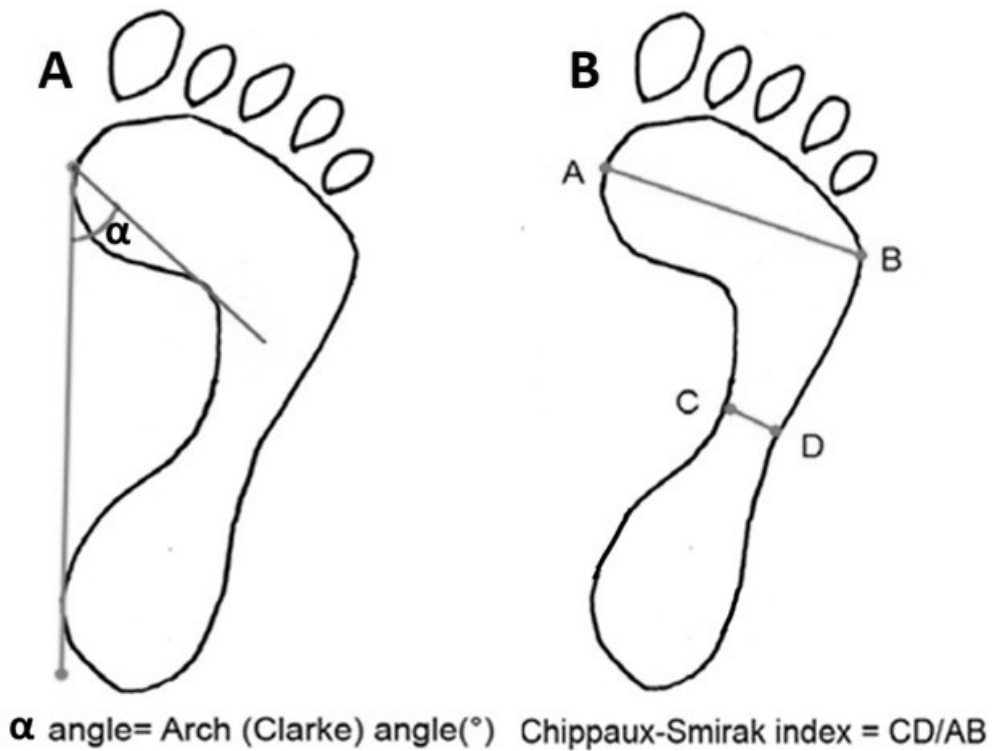
The collected footprints were examined by measuring the Clarke angle and the Chippaux-Smirak index.

Clarke's angle is defined as the angle obtained by a tangent line joining the medial edges of the first metatarsal head and the heel, and the second line that connects the first metatarsal head and the acme of the medial longitudinal arch concavity [3] (**Fig. 1A**). Based on the Clarke's angle value the foot is normal with Clarke's angle between 42° and 54°, flat when the angle is less than 41° and with high medial arch when the Clarke's angle is more than 54°.

Chippaux-Smirak index is the ratio of the maximum support width of the metatarsals to the minimum support width of center of the arch (**Fig. 1B**) [7]. Thus, Chippaux-Smirak index =  $AB/CD \times 100\%$  (**Fig. 1B**) [7]. In the cases with Chippaux-Smirak index between 25% and 45% the foot is considered as normal. If the Chippaux-Smirak index is more than 45% the foot is described as flat (pes planus) and when the index is less than 25% – as high arched foot.

According to these observations and measurements, study participants were divided into three groups: normal, high arched and flat foot, based on both Clarke's angle and Chippaux-Smirak index values. The frequency of Morton's toe in each group was studied.

The statistical data analysis was performed using the  $\chi^2$  test and  $p \leq 0.05$  was accepted as statistical reliability.



**Fig. 1. A.** Clarke's angle ( $\alpha$  angle) is obtained by a tangent line joining the medial edges of the first metatarsal head and the heel, and the second line that connects the first metatarsal head and the acme of the medial longitudinal arch concavity. **B.** Chippaux-Smirak index is the ratio of the maximum support width of the metatarsals (AB line) to the minimum support width of center of the arch (CD line). Thus, Chippaux-Smirak index =  $AB/CD \times 100\%$  [7].

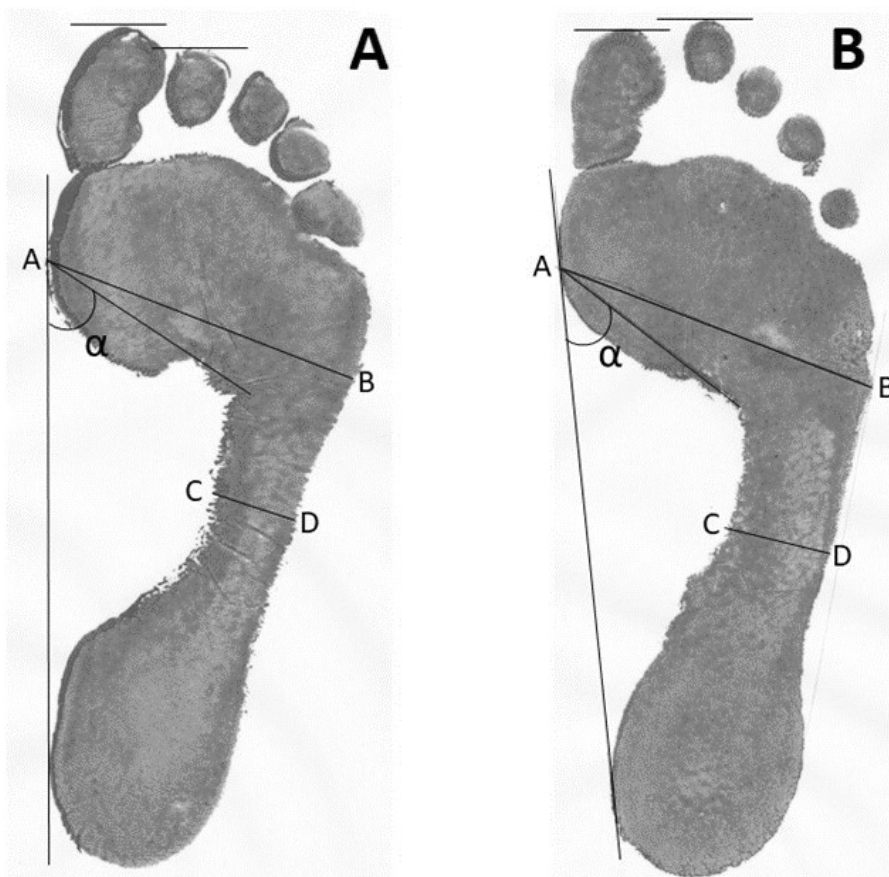## Results

Forty six (46) out of 102 plantograms were positive for Morton's toe or 45% of the participants were with shorter first toe compare to the second one (**Fig 2**).

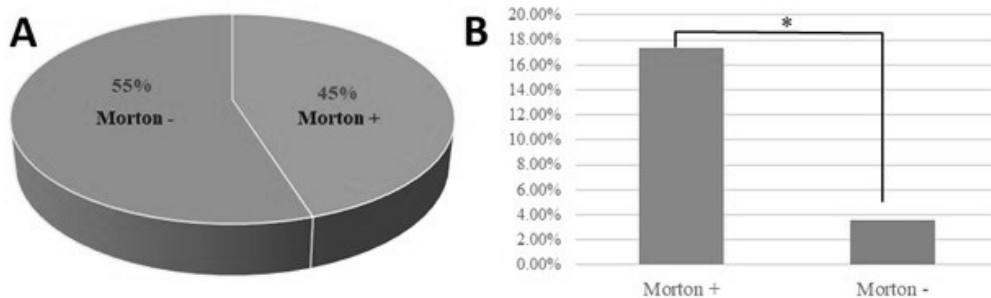
According to the values of Clarke's angle and Chippaux-Smirak index 85 were with normal, seven – with flat and ten persons with high arched foot. Expressed in percentages these results show that 6,86 % of the included footprints are characterized as flat ones and 9,80% as high arched foot.

Within the Morton's toe positive group, 17,40 % of the foot prints were with high medial arch. In the Morton's toe negative group this percentage was 3,58 %.

The further statistical analysis (the  $\chi^2$  test) proved an association between the high arched foot and Morton's toe ( $p \leq 0.05$ ) and showed no association between the flat foot condition and the Morton's toe (**Fig. 3**).



**Fig. 2. A.** Morton's toe negative footprint. **B.** Morton's toe positive footprint (second toe is longer than the first one).  $\alpha$  – Clarke's angle. AB line – the maximum support width of the metatarsals; CD line - the minimum support width of center of the arch. Chippaux-Smirak index =  $AB/CD \times 100\%$ .



**Fig. 3. A.** 45% of all plantograms in our study are Morton's toe positive. **B.** In 17,40 % in the Morton's toe positive group the foot prints were with high medial arch. In the Morton's toe negative group this combination is observed only in 3,58 % ( $\chi^2$  test,  $p \leq 0.05$ ).

## Discussion

Morton's toe is a congenital shortening of the first metatarsal bone. The secondary ossification center is different in this bone and in the other four metatarsal bones. It appears in the proximal end of the first metatarsal and in the distal ends of the second to fifth metatarsal bones. The premature closure of the epiphysis of the first metatarsal causes Morton's toe condition.

The Morton's toe has been observed with varying prevalence in different populations. The results show frequency of the condition between 0,05% and more than 50% [11]. Our data show a high prevalence of Greek foot in the Bulgarian population.

Static foot assessment is one of the commonly used methods to get information and make clinical decisions in order to identify possible etiological factors of the lower extremity dysfunctions and injuries. The results when using only one method are quite variable and in practice the combined use of several parameters in the evaluation of plantograms is preferred. The accuracy of the Clarke's angle itself is estimated to be 68% and the accuracy of the Chippaux-Smirak index – 80%. The experimental results using a combination of indicators show that an accuracy of the result is up to 93% more than the single index [1]. For this reason we combined these two measurements.

The results of this study show that the high arched foot is more common in Bulgarian population than the flat foot. This type of foot is often underestimated as a cause of complaints and problems involving the entire lower limb.

The data showed a higher frequency of high arched foot in Morton positive participants. This is a combination of two conditions that lead to impaired morphology and function of the medial arch, which can disturb the distribution of body weight during gait and result in compensatory changes in adjacent joints of the lower limb and predisposition to low energy trauma. Common complication is metatarsalgia (a pain under heads of metatarsals), predominantly under second toe due to increased weight forces during the propulsive phase of gait. This is because the second metatarsal head is farthest forward and the force is transferred through it. Along with high medial arch, which makes the foot rigid with less surface area for absorbing impact, there is excessive pressure on rearfoot and forefoot areas. This can make the leg susceptible to foot conditions such as heel pain, plantar fasciitis and metatarsalgia [4, 5, 6, 10].

## Conclusions

Morton's toe, which is primarily a genetically determined condition, is very common in the Bulgarian population. The high arched foot is significantly more common than the flat foot. We found that Morton's toe is associated with a higher incidence of high arched foot.

*Acknowledgements:* We thank the colleagues from the Medical Center for Rehabilitation and Sports Medicine -1, Varna for the opportunity to use their base.

## References

1. **Aruntammanak, W., Y. Aunhathaweessup, W. Wongseree, A. Leelasantitham, S. Kiattisin.** Diagnose flat foot from foot print image based on neural network. – *Computer Science*, **1** 2013. Available at <https://DOI:10.1109/BMEICON.2013.6687684> Corpus ID: 27733508
2. **Ayub, A., S. H. Yale, C. Bibbo.** Common foot disorders. – *Clin. Med. Res.*, **3**, 2005, 116-119.
3. **Gray, H.** *Anatomy of the human body* (Ed. W.H.Lewis), 20th edition, NY, 2000. Available at <http://www.Bartleby.com>.
4. **Hong, W. H., Y. H. Lee., H. C. Chen, Y.C. Pei, C. Y. Wu.** Influence of heel height and shoe insert on comfort perception and biomechanical performance of young female adults during walking. – *Foot Ankle Int.*, **26**, 2005, 1042-1048.
5. **Kouchi, M., M. Kimura, M. Mochimaru.** Deformation of foot cross-section shapes during walking. – *Gait Posture*, **30**, 2009, 482-486.
6. **Lee, Y. H., W. H. Hong.** Effects of shoe inserts and heel height on foot pressure, impact force, and perceived comfort during walking. – *Appl. Ergon.*, **36**, 2005, 355-362.
7. **Open University of Cyprus. Nicosia.** Cyprus Available at: <http://www.omim.org/entry/189200>
8. **Ozer, C. M.** Evaluation of the sole morphology of professional football players. – *International Sportmed Journal*, **13**, 2012, 1, 8-17.
9. **Papaliodis, D. N., M. A. Vanushkina, N. G. Richardson, J. A. DiPreta.** The foot and ankle examination. – *Med. Clin. N. Am.*, **98**, 2014, 181–204.
10. **Umberto, A. M., C. Valentina, L. Mangiavini, M. Palmucci.** Is it still current to talk about first ray hypermobility? – *Acta Biomed.*, **90**, 2019, Supplement 1, 32-35.
11. **Vounotrypdis, P., P. Noutsou.** Greek foot: is it a myth or reality? An epidemiological study in Greece and connections to past and modern global history. – *British Journal of Rheumatology*, **54**(suppl\_1), 2015, i182-i183.
12. **Xiong, S., R. S. Goonetilleke, C. P. Witana, T. W. Weerasinghe, E. Au.** Foot arch characterization: a review, a new metric and a comparison. – *J. Am. Podiatr. Med. Assoc.*, **100**, 2010, 14-24.