

Anthropology and Anatomy

Anthropological Investigations of Necropolis from the Ottoman Period Revealed during the Excavations of Archaeological Site “Trayanovi Vrata”, Located in the Kapiyata Locality, Kostenets Municipality

Nadezhda Atanassova

*Institute of Experimental Morphology, Pathology and Anthropology with Museum,
Bulgarian Academy of Sciences, Sofia, Bulgaria*

* Corresponding author e-mail: naditimeva@gmail.com

In 2016 were carried out excavations of archaeological site “Trayanovi vrata”, located in the Kapiyata locality, Kostenets municipality (Sofia Province). In one of the trenches was excavated a Christian necropolis with 15 graves (15th-17th c.) of civilian population. The burial ritual was inhumation. The aim of the present study is to provide generalized anthropological information about the skeletons in this necropolis: age-at-death and sex distribution, stature, body mass and paleopathological changes. During the anthropological investigation have been identified remains from 19 individuals. In this skeletal series predominate the subadults in a ratio of 1:0.73, as the most numerous group is this of the infants up to the age of 7 (47.37%). The identification of porous skull lesions in subadult and adult individuals is indicative of anaemic conditions in the population.

Key words: Christian necropolis, Ottoman period, paleoanthropological analysis, paleopathology

Introduction

The excavations of archaeological site “Trayanovi vrata”, located in the Kapiyata locality, Kostenets municipality (Sofia Province), were carried out in 2016 under the leadership of Gergana Kabakchieva and Vladislav Todorov. The main purpose of this research was to reveal the remains of the famous “Trayan’s gate” in the ancient pass “*Suki*”. In one of the trenches was excavated a Christian necropolis with 15 graves of civilian population. The burials were marked with stones and orientated West-East. In three of the burial structures have been found jewellery, by which the archaeologists

dated the necropolis in the 15th-17th c. [9]. The burial ritual was inhumation. During the field anthropological investigation have been identified bone remains from 19 individuals. **The aim** of the present study is to provide generalized anthropological information about the skeletons in this necropolis: age-at-death and sex distribution, stature, body mass and paleopathological bone changes.

Material and Methods

This paper includes results of detailed anthropological investigation of 19 inhumated skeletons from Christian necropolis at archaeological site “Trayanovi vrata”, Kapiyata locality, Kostenets municipality (Sofia Province). The human bone material is in poor condition. The skeletons are fragmented and incompletely represented. A fully preserved skull was found only in one case (grave No. 9).

Using well established anthropological methods [1, 3, 4, 5, 6, 7, 8, 10, 11, 16, 18], metric and scapular analyzes of the osteological materials were made in order to determine the age-at-death and sex of the investigated individuals. The reconstruction of the height (by Pearson-Lee [14] and Trotter-Gleser [17]) and the evaluation of the body mass (by Ruff et al. [15]) of adults were carried out depending on the condition of the presented bones. The health status of the studied population was assessed by age and sex distribution of the identified morphological bone changes by Aufderheide, Rodriguez-Martin [2], Ortner, Putschar [13] and Ortner [12].

Results and Discussion

Age-at-death and sex distribution (Table 1)

The age and sex distribution of the investigated buried individuals is as follows: one fetus (38-40 gestational week) and eight children in *Infans I*; two female juveniles; only one male in the age group *Adultus* (20-40 years); four men in *Maturus* (40-60 years); two males and one female in the group *Adultus+* (>18/20 years). In this skeletal series predominate the subadults in a ratio of 1:0.73, as the most numerous group is this of the infants up to the age of 7 years (47.37%). Concerning adults, males from the age group *Maturus* prevail and only one female was defined at the age over 18/20 years. None individual from both sexes was identified in the elderly (>60 years).

Table 1. Age-at-death and sex distribution of the investigated individuals from the necropolis at archaeological site “Trayanovi vrata” (Sofia Province).

Age group																			Total			
<i>Fetus</i>	<i>Inf I</i>	<i>Inf II</i>	<i>Juvenis</i>			<i>Adultus</i>					<i>Maturus</i>			<i>Senilis</i>		<i>Adultus+</i>						
			♂	♀	♀	♂	♂?	♀	♀?	♂	♀	♀	♂	♀	♂	♀	♂	♂?		♀	♀?	♀
1	8	0	0	2	0	1	0	0	0	0	4	0	0	0	0	0	2	0	1	0	0	19

Stature and body mass estimation (Fig. 1)

The height and body mass have been reconstructed in only one adult female individual (grave No. 1) who was with “middle” stature and 63.39 kg body weight. Concerning the male sex, the height varies from 161.69 cm to 168.31 cm by the formula of Pearson-Lee [14] and from 166.59 cm to 173.33±3.71 cm by the formula of Trotter-Gleser [17]. It is established that most of the male individuals were with “above middle” and “high” stature. The body mass is estimated in three males and the values are as follows: 62.83 kg (grave No. 5); 66.53 kg (grave No. 7) and 78.87 kg (grave No. 12).

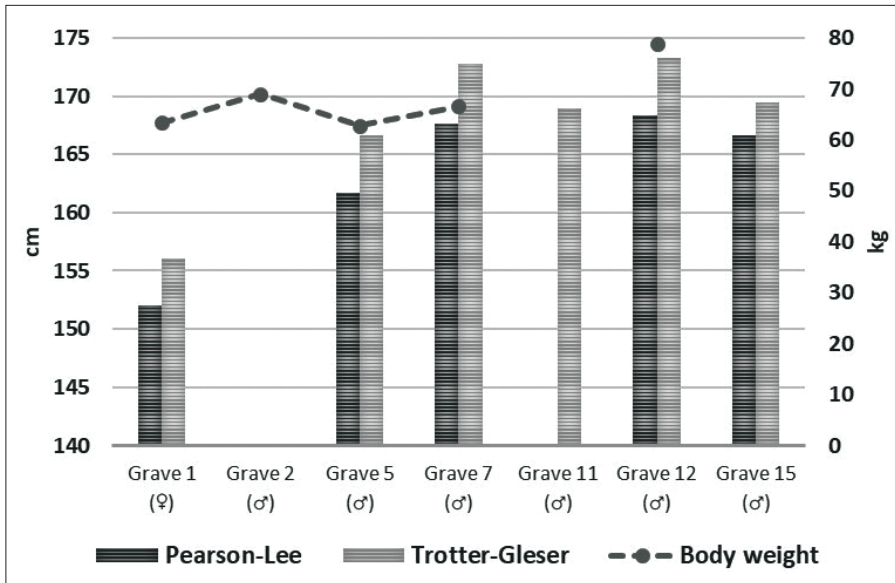


Fig. 1. Reconstruction of stature and body mass of the investigated individuals from the necropolis at archaeological site “Trayanovi vrata” (Sofia Province).

Paleopathological analysis

In the series have not been identified jaw and tooth pathology in children, except for one child in *Infans I* (grave No. 4) with localized hypoplastic pit (BP) on the buccal enamel surface of the lower second deciduous molars. Despite the small number (6) of studied individuals with permanent dentition, in five of them (only males) a large number (57) of intravital teeth loss is observed.

Traumatic cranial traces are registered only in a mature man (Grave No. 9) – on nasal bones (Fig. 2) and right parietal bone. The largest number of cases have been identified with secondary skull morphological changes resulting from slightly expressed form of *cribra orbitalia* (two children in *Infans I* and one male individual in age group *Adultus*) and *porotic hyperostosis* (a male in *Maturus*). The identification of these porous skull lesions in subadult and adult individuals is indicative of anaemic conditions in the population.

Morphological changes of the postcranial skeleton were not identified in subadults from the series. Pathology of the postcranial bones is observed in seven (87.5%) of the adults buried in the necropolis. In the series mainly males in age group *Maturus*

(40-60 years) are affected. It is established only one case with *spina bifida occulta* in an adult female (grave No. 1). Another type of malformation of *os sacrum* (sacralization of the fifth lumbar vertebra), was found in the skeleton (grave No. 11) of a male individual in *Adultus*. Most common in the series are degenerative joint diseases (DJD) of the spine moreover in their severe forms. Ankylosing spondylitis is diagnosed in the lumbar region of a male individual in age group *Adultus* (grave No. 11) and in the thoracic vertebrae of a male in *Maturus* (grave No. 9). A mild form of spondylosis and spondyloarthrosis in all sections of the spine is found in one of the buried men in group *Maturus* (grave No. 12). Slightly pronounced DJD of the upper and lower limbs are recorded in two males (graves No. 2 and 5) – on both shoulder and knee joints. In one of these individuals (grave No. 5) is identified and *myositis ossificans* on the left *humerus* and *tibia*, with a probable etiology of chronic trauma, resulting from intense physical activity. Bilateral epicondylitis of the shoulder bones and a trace of healed fracture on a fragment of left rib were diagnosed in a male from age group *Maturus* (grave No. 12). In one of the buried male individuals is registered also benign bone tumor formation (*osteoma*) on the right *tibia* (grave No. 7).

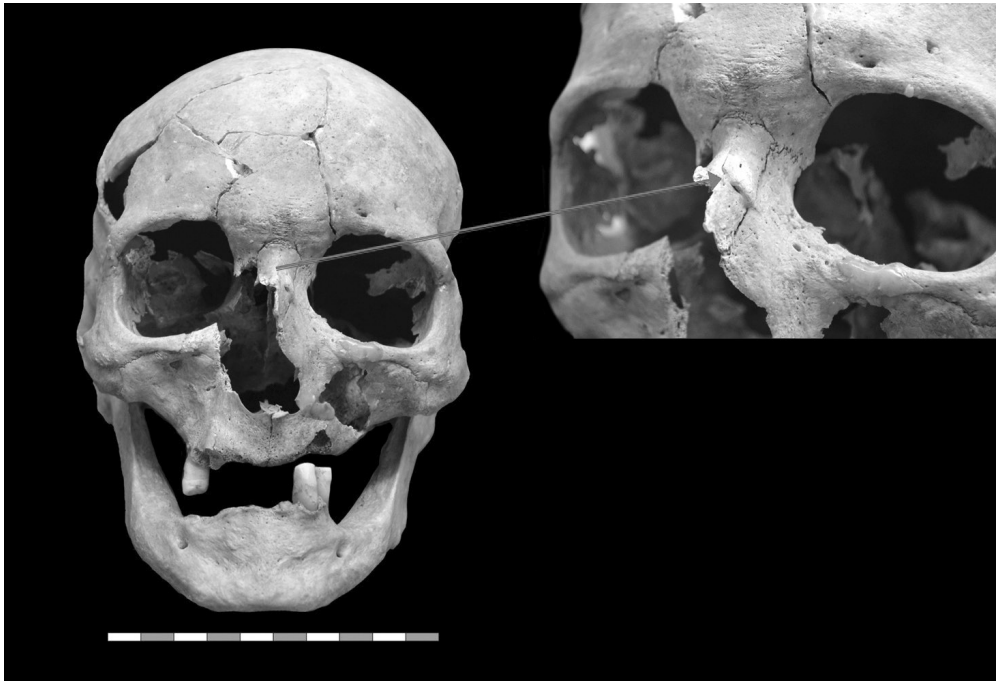


Fig. 2. Grave No 9. Male (50-55 years). Traumatic traces on nasal bone.

Conclusions

Most of the pathological bone changes (mainly degenerative joint diseases) of the postcranial skeleton are registered in male individuals, even in the age group *Maturus*, which suggests a premature and rapid aging of bone-joint apparatus, probably due to intensive and heavy physical works.

References:

1. **Alekseev, V.** *Osteometry, methods of anthropological study*. Moscow, Nauka, 1966, 249 pp. [in Russian].
2. **Aufferheide, C., C. Rodriguez-Martin.** *The Cambridge encyclopedia of human paleopathology*. Cambridge University Press, 1998, 478 pp.
3. **Bass, W.** *Human osteology: a laboratory and field manual of the human skeleton*. University of Missouri, Special publication no. 2 of the Missouri Archaeological Society, 2005, 365 pp.
4. **Brothwell, D.** *Digging up bones*. London, British Museum of Natural History, 1965, 196 pp.
5. **Buikstra, J., D. Ubelaker.** *Standards for data collection from human skeletal remains: Proceedings of a seminar at the field museum of natural history*. Fayetteville, AK, Arkansas Archaeological Survey, 1994, 272 pp.
6. **Fazekas, I. Gy., F. Kósa, E. Kerner.** *Forensic fetal osteology*. Budapest, Akademiai Kiado, 1978, 413 pp.
7. **Ferembach, D., I. Schwidetzky, M. Stloukal.** Recommendations for age and sex diagnosis of skeletons. – *J. Hum. Evol.*, **9**, 1980, 517-549.
8. **Gerasimov, M.** *Reconstruction of the face by the skull*. Moscow, Nauka, 1955, 586 pp. [in Russian].
9. **Kabakchieva, G.** Excavation of the “Trajanovi vrata” (“Trajan’s gate”) in Kapiyata locality, Kostenets municipality, Sofia province. – *Archaeological discoveries and excavations in 2016, 2017*, 441-444 [in Bulgarian].
10. **Maresh, M.** Measurements from roentgenograms. – In: *Human growth and development* (Ed. R.W. McCammon), Springfield IL: C.C. Thomas, 1970, 157–200.
11. **Meindl, R., C. Lovejoy.** Ectocranial suture closure: a revised method for the termination of skeletal age-at-death based on lateral-anterior sutures. – *Am. J. Phys. Anthropol.*, **68**, 1985, 57-66.
12. **Ortner, D. J.** *Identification of pathological conditions in human skeletal remains*. 2nd Edition. San Diego, Academic Press, 2003, 647 pp.
13. **Ortner, D.J., J. Putschar.** *Identification of pathological conditions in human skeletal remains*. Washington, Smithsonian Institution Press, 1981, 499 pp.
14. **Pearson, K.** Mathematical contributions to the theory of evolution. V. On the reconstruction of the stature of prehistoric races. – *Philosophical Transactions of the Royal Society of London. Series A, Containing Papers of Math. or Phys. Character* (1896-1934), **192**, 1899, 169–244.
15. **Ruff, C. B., W. W. Scott, A. Y. Liu.** Articular and diaphyseal remodeling of the proximal femur with changes in body mass in adults. – *Am. J. Phys. Anthropol.*, **86(3)**, 1991, 397–413.
16. **Tood, T.W.** Age changes in the pubic bone I: the male white pubic. – *Am. J. Phys. Anthropol.*, **3**, 1920, 285-334.
17. **Trotter, M., G. Gleser.** Estimation of Stature from Long Bones of American Whites and Negroes. – *Am. J. Phys. Anthropol.*, **10**, 1952, 463-514.
18. **Zubov, A.** *Odontology. Methods of anthropological investigations*. Moscow, Nauka, 1968, 200 pp. [in Russian].