

Expression of Ghrelinpositive Cells in the Stomach of the Rat

*S. Hamza**, *I. Vulkova**, *M. Gulubova***, *P. Atanasova****, *D. Sivrev**

**Department of Anatomy, Faculty of Medicine, St. Zagora, Bulgaria*

***Department of General and Clinical Pathology, Faculty of Medicine, St. Zagora, Bulgaria*

****Department of Anatomy, Histology and Embryology, University of Medicine, Plovdiv, Bulgaria*

Ghrelin is a relatively new-found hormone. The cells which express ghrelin in the largest amount are in the ventricular fundus. The aim of the study was by immunocytochemical methods to establish the presence of ghrelinpositive cells in the lining of the stomach. Ghrelinpositive cells are visualized in the deeper parts of the lining taken from the area of ventricular fundus. Their amount is greater near the border with the muscle sheath. Individual cells containing granules with ghrelin was found in the superficial parts of the muscular coat and close to the surface of the lining.

Key words: ghrelin, stomach, ghrelinpositive cells, expression.

Introduction

Following the discovery of new hormone ghrelin by Kojima et al. [8] research on it increases every year [9]. Ghrelin is a hunger hormone with gastropokinetic properties [5] but the factors controlling ghrelin secretion from the stomach are not too elucidated. Malik et al. [10] showed that even in the absence of caloric deficiency, ghrelin may favor food consumption by enhancing the hedonic and incentive responses to food-related cues. Ghrelin also has important effects on gastrointestinal (GI) motility, which may contribute to appetite signaling [5].

Most researchers have focused on the impact of hormones on metabolism, energy balance, the level of blood sugar, gastric emptying etc. [1, 2, 3, 12]. Kojima and Kanda continues his research on the structure and function of the newly hormone [8]. There are many studies on the physiological effects and potential clinical applications of ghrelin but too few are purely theoretical developments on the expression of ghrelinpositive cells in the body [11, 13, 14]. The aim of the study was to establish the expression of ghrelinpositive cells in the lining of the stomach. For the implementation of the objective identified the following main tasks: 1) to visualize any ghrelin productive cells in the fundus by immunocytochemical methods; 2) to determine their localization in the gastric mucosa by light microscopy.

Materials and Methods

We examined the expression of ghrelin-positive cells in mucosa of the rat ventricular fundus by immunohistochemistry. Stomach tissue samples were collected from the fundus region of 3 male mature rats strain Wistar subject to the European Directive 2010/609 for animal welfare and with the permission of the Ethics Committee at the Faculty of Medicine – Stara Zagora.

We applied the “dropping” of ultra-thin (4 μm) sections with antibody Ghrelin (H-40) SC-50 297, produced by Santa Cruz, USA, and visualization ghrelin positive cells – detection system Dako - En Vision FLEX - Mini Kit.

Results

Immunostaining of ghrelin was detected in the deeper parts of the lining taken from the area of ventricular fundus. Immunohistochemistry demonstrated the presence of ghrelin cells near the proper gastric glands. Their amount is greater near the border with the muscle sheath (**Fig. 1**).

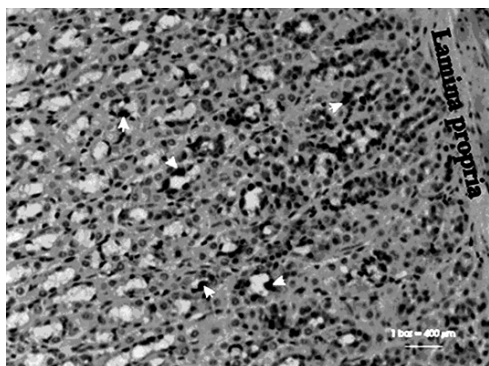


Fig 1. Ghrelin-positive cells near the border with the muscle sheath

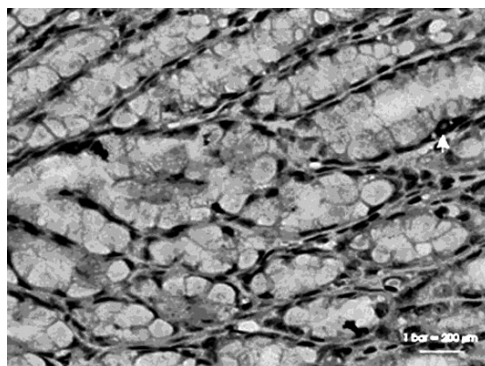


Fig 2. Ghrelin-positive cells near the border with the muscle sheath

A few cells containing ghrelin granules were found in the deep layers of the mucous membrane of the stomach, superficial parts of the muscular tunic and close to the surface of the lining (**Fig. 2**).

Discussion

Ghrelin is a 28-amino acid peptide with an octanoyl modification, which is mainly produced by the “X/A-like” cells of the oxyntic glands of the stomach [8, 9] in response to conditions of negative energy balance.

According to Abbuki et al. [15] the localization of ghrelin cells in the stomach was similar in mice, rats and hamsters. No immunoreactivities were detected in any animals when antiserum absorbed by excessive ghrelin was used [15]. Most authors describe expression of ghrelin positive cells in the deep part of the gastric mucosa, but no reports of the existence of such cells in the muscle layer.

Hayashida et al. [4] investigate ghrelin in domestic animals, its distribution in stomach and a possible role. Jason [6] searches ghrelin in the summer flounder – immunolocalization to the gastric glands and action on plasma cortisol levels. Their reports were similar to our results of the ghrelin cellpositive expression [7].

Conclusions

1. Ghrelin-producing cells are characteristic of the venter and operate basic on digestive system.
2. Greatest amount ghrelinpositive cells found in the gastric mucosa of ventricular fundus.
3. Some cells are visualized in the deep layers of the mucous membrane of the stomach, near the glands, but there are single cells in muscle sheath.

References

1. **Asakawa, A., A. Inui, T. Kaga, H. Yuzuriha, T. Nagata, N. Ueno, S. Makino, M. Fujimiya, A. Nijjima, M. Fujino, and M. Kasuga.** Ghrelin is an appetite-stimulatory signal from stomach with structural resemblance to motilin. – *Gastroenterology*, **120**, 2001, 337-345.
2. **Broglio, F., E. Arvat, A. Benso, C. Gottero, G. Muccioli, M. Papotti, A. van der Lely, R. De-ghenghi, E. Ghigo.** Ghrelin, a natural GH secretagogue produced by the stomach, induces hyperglycemia and reduces insulin secretion in humans. – *J. Clin. Endocrinol. Metab.*, **86**, 2001, 5083-5086.
3. **Dornoville, C., E. Lindström, P. Norlén, R. Håkanson.** Ghrelin stimulates gastric emptying but is without effect on acid secretion and gastric endocrine cells. – *Regul. Pept.*, **120**, 2004, 23-32.
4. **Hayashida, T., K. Murakami, K. Mogi, M. Nishihara, M. Nakazato, M. S. Mondal, Y. Horii, M. Kojima, K. Kangawa, N. Murakami.** Ghrelin in domestic animals: distribution in stomach and its possible role. – *Domest. Anim. Endocrinol.*, **21**, 2001, 17-24.
5. **Janssen, S., J. Laermans, P. Verhulst, T. Thijs, J. Tack, I. Depoortere.** Bitter taste receptors and α -gustducin regulate the secretion of ghrelin with functional effects on food intake and gastric emptying. – *PNAS*, **108**(5), 2011, 2099.
6. **Jason, P., A. Philip, J. Specker.** Ghrelin in the summer flounder: Immunolocalization to the gastric glands and action on plasma cortisol levels. – *Comparative Biochemistry and Physiology: Part A. – Molecular & Integrative Physiology*, **152**, 2009, 268-272.
7. **Kaya, H., I. Sakata, K. Yamamoto, A. Koda, T. Sakai, K. Kangawa, S. Kikuyama.** Identification of immunoreactive plasma and stomach ghrelin, and expression of stomach ghrelin mRNA in the bullfrog, *Rana catesbeiana*. – *General and Comparative Endocrinology*, **148**, 2006, 236-244.
8. **Kojima, M., H. Hosoda, Y. Date, M. Nakazato, H. Matsuo, K. Kangawa.** Ghrelin is a growth-hormone-releasing acylated peptide from stomach. – *Nature*, **402**, 1999, 656–660.
9. **Kojima, M., K. Kangawa.** Ghrelin: structure and function. – *Physiol. Rev.*, **85**, 2005, 495-522.
10. **Malik, S., F. McGlone, D. Bedrossian, A. Dagher.** Ghrelin modulates brain activity in areas that control appetitive behavior. – *Cell. Metab.*, **7**, 2008, 400-409.
11. **Matsubara, M., I. Sakata, R. Wada, M. Yamazaki, K. Inoue, T. Sakai.** Estrogen modulates ghrelin expression in the female rat stomach. – *Peptides*, **25**, 2004, 289–297.
12. **Sakata, I., J. Yang, C. Lee, S. Osborne-Lawrence, S. Rovinsky, J. Elmquist, J. Zigman.** Colocalization of ghrelin O-acyltransferase and ghrelin in gastric mucosal cells. – *Am. J. Physiol. Endocrinol. Metab.*, **297**, 2009, 134-141.
13. **Sakata, I., K. Nakamura, M. Yamazaki, M. Matsubara, Y. Hayashi, K. Kangawa, T. Sakata, I., T. Tanaka, M. Matsubara, M. Yamazaki, S. Tani, Y. Hayashi, K. Kangawa, T. Sakai.** Post-natal changes in ghrelin mRNA expression and in ghrelin-producing cells in the rat stomach. – *J. Endocrinol.*, **174**, 2002, 463-471.
14. **Sakata, I., T. Mori, H. Kaiya, M. Yamazaki, K. Kangawa, K. Inoue, T. Sakai.** Localization of Ghrelin-Producing Cells in the Stomach of the Rainbow Trout (*Oncorhynchus mykiss*). – *Zoological Science*, **21**(7), 2004, 757-762.

15. **Yabuki, A., T. Ojima, M. Kojima, Y. Nishi, H. Mifune, M. Matsumoto, R. Kamimura, T. Masuyama, S. Suzuki.** Characterization and species differences in gastric ghrelin cells from mice, rats and hamsters. – *J. Anat.*, **205**, 2004, 239-246.

Address for correspondence
Sevinch Hamza
Department of Anatomy
Faculty of Medicine
11 Armeyska Str.
6000 Stara Zagora
Bulgaria
e-mail: dsivrev@abv.bg